

**Joint Symposium for JSVS2016, ISHAM-Veterinary Mycology
and -Medical Phycology Working Groups**

"Veterinary Mycology and Phycology 2016"

**9:30 to 15:50 on 8th September 2016
at Nihon University College of Bioresource Sciences
in Fujisawa, Japan**



FINAL PROGRAMME & ABSTRACTS

Location: Building 1, Room 123

Nihon University College of Bioresource Sciences

1866, Kameino Fujisawa, Kanagawa 2520880, Japan

Website of the College: <http://hp.brs.nihon-u.ac.jp/~english/about/>

Access: <http://hp.brs.nihon-u.ac.jp/~english/access/>

About ISHAM-Veterinary Mycology Working Group (ISHAM-VMWG)

This working group has been established by a group of experts under the umbrella of International Society for Human and Animal Mycology (ISHAM) to support all scientific aspects that deals on mycology and veterinary sciences, including:

- Diagnosis & identification of veterinary pathogenic fungi
- Pathophysiology and immunology of fungal diseases in animals
- Epidemiology, prevention, control and eradication of animal mycoses
- Vaccine development, pharmacokinetics and pharmacodynamic evaluation of Antifungals in Animals
- Fungal zoonoses
- Mycotoxins and Mycotoxicosis
- Standardization of animal model on invasive fungal infections and use of alternatives

We aim to share expertise among all countries around the globe to provide strong framework of existing knowledge, as we may learn a lot from each other. We collaborate with other ISHAM-working groups, international societies, regulatory agencies and governmental authorities.

Participation in this working group is open to everybody who interested to join this international network on the area of veterinary mycology.

ISHAM-VMWG organizing committee

- Prof. Jacques Guillot
- Dr. Amir Seyedmousavi
- Dr. Andrea Peano

HP: <http://www.veterinarymycology.org/index.html>

About ISHAM Medical Phycology : Protothecosis and Chlorellosis Working Group (ISHAM-MPWG)

We established a WG under the umbrella of ISHAM for supporting all scientific aspects that deals with “Medical Phycology: Protothecosis and Chlorellosis” (Application submitted on December 29, 2013 and approved on May 4, 2014).” Algal infections are so-called “orphan diseases” that have been studied principally by medical mycologists because of the yeast-like appearances of the causative algae.

This WG aims to be a forum where specialists in algal infections in humans and animals may join efforts to build a network to increase the knowledge in this area. More precise announcements of our program will appear at ISHAM news. It is planned to have our WG meeting during the next ISHAM congress in 2015. A subsequent plan will then be organized. The concept of this WG in general will be launched at the near future in a webpage < <http://medicalphycology.org/>>.

Coordinators:

John R. Todd, M.D. (U.S.A.)

Koichi Makimura, M.D., PhD. (Japan)

Participation in ISHAM-MPWG is open to any scientists who are interested to join this international network on the area of Medical Phycology.

Applications must be sent to Dr. Rui Kano (WG Secretary)



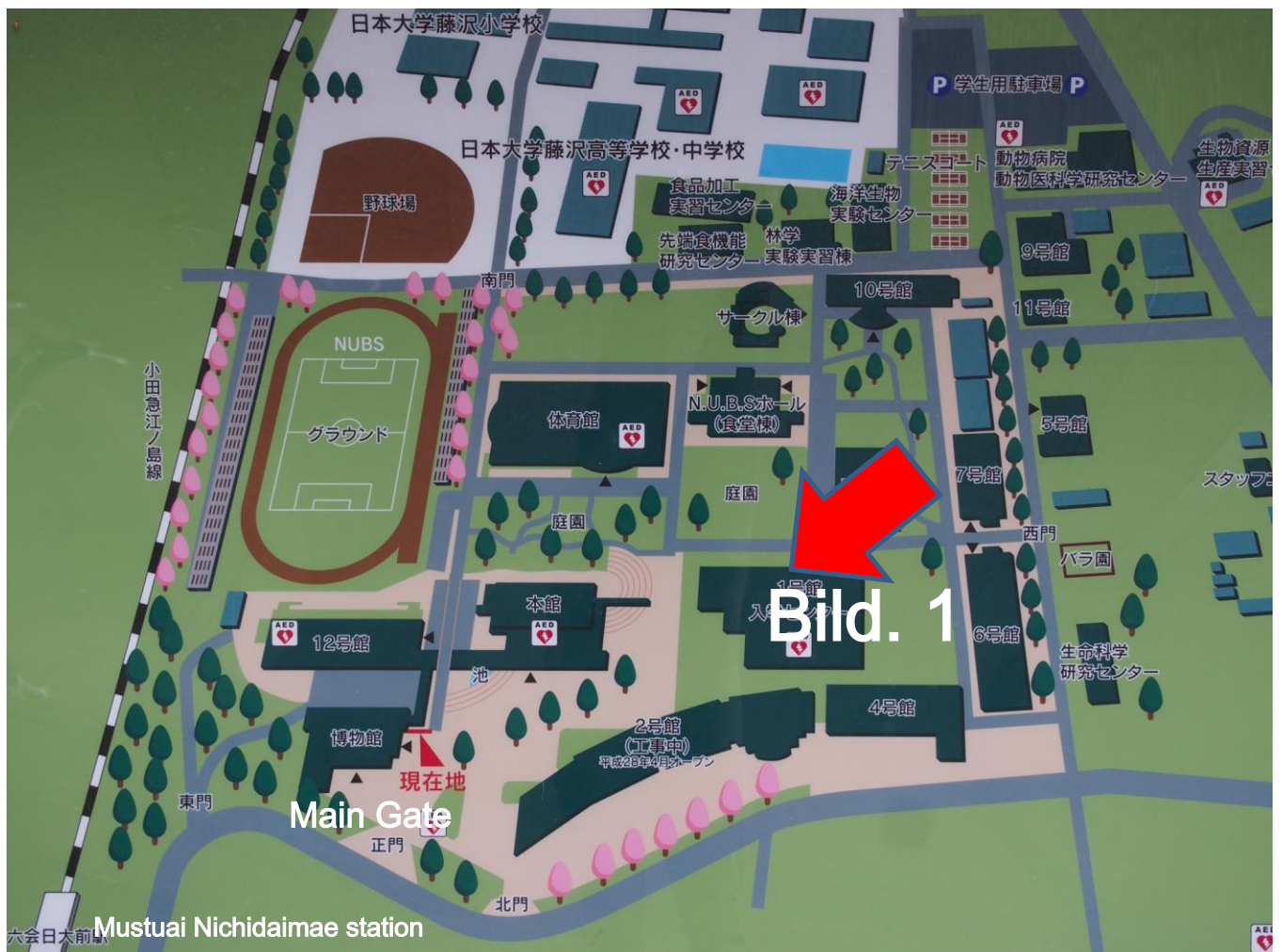
Registration fee

- Free for students, post-docs, JSVS registered members
- JPN Yen 5,000 for academia

For registration/detailed information please contact course directors

- Dr. Rui Kano (kano.rui@nihon-u.ac.jp)
- Dr. Amir Seyedmousavi (S.Seyedmousavi@gmail.com)

Map of the Nihon University College of Bioresource Sciences



Program

9:30 to 15:30 on 8th September 2016 at Nihon University College of Bioresource Sciences in Fujisawa, Japan

Co-chairperson : Prof. A. Hasegawa (Japan), Prof. K. Makimura (Japan) and
Dr. S. Y. Lim (Malaysia)

Introduction

General taxonomy and classification of Fungi

Dr. A. Seyedmousavi (USA) 30 min(Q & A 5min)

Mycoses in Companion Animals

1. *Malassezia* dermatitis in dogs and cats: current recommendations and relevance of topical treatments

Pr. J. Guillot (France) 30 min(Q & A 5min)

2. Fungal rhinosinusitis: emerging agents of aspergillosis in cats

Dr. V. Barrs (Australia) 30 min(Q & A 5min)

Break 10min

3. Cryptococcosis in companion animals and wildlife

Dr. R. Malik (Australia) 30 min(Q & A 5min)

4. *Microsphaeropsis arundinis* - an emerging infectious disease of humans and animals in Australia

Dr. R. Malik (Australia) 20 min(Q & A 5min)

Lunch 12:00-13:00

5. Sporotrichosis: an “old” disease but an ongoing threat for animal and human health

Pr. J. Guillot (France) 30 min(Q & A 5min)

6. Protothecosis in animals in Austraria

Dr. R. Malik (Australia) 20 min(Q & A 5min)

7. Scedosporiosis in companion animals: another emerging mycosis?

Dr. V. Barrs (Australia) 20 min(Q & A 5min)

Break 10min

Mycoses in farm Animals and Antifungal Drug Resistance

8. Aspergillosis: a real threat for poultry industry?

Pr. J. Guillot (France) 30 min(Q & A 5min)

9. Azole resistance in *Aspergillus fumigatus* in EU: why it is increasing in the world ?

Dr. A. Seyedmousavi (USA) 30 min(Q & A 5min)

10. Azole farm fungicide and azole resistance in *Aspergillus fumigatus*: is it increasing in Japan ?

Dr. R. Kano (Japan) 30 min(Q & A 5min)

Party 16:30~

SPEAKERS PRESENTATIONS



Dr. Seyedmojtaba (Amir) Seyedmousavi

Laboratory of Clinical Infectious Diseases (LCID), National Institute of Allergy and Infectious Diseases (NIAID), National Institutes of Health (NIH), Bethesda, MD 2089, United States of America



Prof. Guillot Jacques, DVM, PhD, dipl. EVPC

Parasitology-Myecology-Dermatology Unit, DSBP, Ecole nationale vétérinaire d'Alfort, Maisons-Alfort, France



Prof. Vanessa R. Barrs,

Faculty of Veterinary Science, School of Life and Environmental Sciences, The University of Sydney NSW 2006 Australia



**Prof. Richard Malik, DVSc MVetClinStud Stud PhD FACVS
FASM**

Centre for Veterinary Education and Faculty of Veterinary Science,
The University of Sydney. Australia



Dr. Rui Kano

Veterinary Pathobiology, College of Bioresource Sciences,
Nihon University, 1866 Kameino, Fuzisawa, Kanagawa 252-0880,
Japan

General taxonomy and classification of Fungi

Dr. Seyedmojtaba (Amir) Seyedmousavi

Laboratory of Clinical Infectious Diseases (LCID), National Institute of Allergy and Infectious Diseases (NIAID), National Institutes of Health (NIH), Bethesda, MD 20892

United States of America

Tel: [\(301\) 402-5139](tel:3014025139), Email: Seyedmousavi@nih.gov

Fungal infections today are among the most difficult to manage diseases in both humans and animals, particularly in the hosts experiencing immunosuppression or underlying predisposing factors.

Among the estimated 1.5 to 5 million fungal species on the planet Earth, only few hundred cause disease in humans and animals.

This lecture intends to highlight recent changes in the taxonomy and nomenclature of medical and veterinary important molds and yeasts, according to recent developments, in the phylogenetic and molecular genomics.

References:

1. De Hoog GS. Et al. 2000. Atlas of Clinical Fungi, 2nd ed. Centraalbureau voor Schimmelcultures, Utrecht.
2. Köhler JR. et al. 2014. The spectrum of fungi that infects humans. 3;5 (1): a019273. Cold Spring Harb Perspect Med.

***Malassezia* dermatitis in dogs and cats: current recommendations and relevance of topical treatments**

Guillot Jacques^{1,2}, Cavana Paola^{2,3}, Crosaz Odile², Petit Jean-Yanique^{1,4}, Chermette René^{1,2}

1. Research group Dynamyc, UPEC, EnvA, Faculty of Medicine, Créteil, France

2. Parasitology-Mycology-Dermatology Unit, DSBP, Ecole nationale vétérinaire d'Alfort, Maisons-Alfort, France

3. Veterinary Faculty, Turin University, Italy

4. Institut de Recherche Clinique d'Alfort, Ecole nationale vétérinaire d'Alfort, Maisons-Alfort, France

Malassezia yeasts belong to normal cutaneous or mucosal microbiota of many warm-blooded vertebrates. These fungi are now recognized as opportunistic pathogens that play a significant role in the development of different human and animal diseases such as otitis externa or seborrhoeic dermatitis. The clinical signs of *Malassezia* dermatitis are not pathognomonic but *Malassezia* dermatitis should be routinely suspected in dogs and cats with inflammatory skin diseases, especially those with erythema and or greasy exudation as a dominant presenting sign. The diagnosis is based on clinical signs, presence of elevated numbers of yeasts on lesional skin, and a clinical and mycological response to antifungal therapy. In veterinary practice, yeast numbers are most usefully assessed by cytological examinations of direct impression smears. The control of *Malassezia* dermatitis usually includes the administration of antifungal drugs and requires the identification and correction of the underlying diseases. An evidence-based review recommended with fair evidence systemic drugs as ketoconazole or itraconazole and with good evidence topical therapy with 2% miconazole nitrate and 2% chlorhexidine gluconate shampoo for *Malassezia* dermatitis treatment in dogs (Nègre *et al.* 2008). However, systemic antifungal agents may be associated with side effects and high cost. Since *M. pachydermatis* is located on the stratum corneum, topical therapy alone may be sufficient to resolve the clinical signs of infection or may allow reducing the duration of systemic therapy. Shampoo therapy is especially suitable for generalized *Malassezia* infection but may also be beneficial as a preventive to decrease the recurrence rate. We recently demonstrated that a weekly 2% climbazole shampoo application for two weeks achieved a *Malassezia* reduction of 94% after the

second application and 15 days after the last shampoo a *Malassezia* CFU reduction of 69% (Cavana *et al.* 2015a). We also demonstrated that once or twice daily applications of wipes soaked in antiseptic and antifungal agents are effective to reduce *M. pachydermatis* population sizes on canine skin. The *in vivo* activity of wipes was supported by *in vitro* tests. Wipes may be useful for treating lips, interdigital spaces, perianal area, and skin fold frequently affected by *Malassezia* overgrowth (Cavana *et al.* 2015b).

References

- Cavana P, Petit JY, Perrot S, Guechi R, Marignac G, Reynaud K, Guillot J. Efficacy of a 2% climbazole shampoo for reducing *Malassezia* population sizes on the skin of naturally infected dogs. *J Mycol Med* 2015a, 25:268-73.
- Cavana P, Peano A, Petit JY, Tizzani P, Perrot S, Bensignor E, Guillot J. A pilot study of the efficacy of wipes containing chlorhexidine 0.3%, climbazole 0.5% and Tris-EDTA to reduce *Malassezia pachydermatis* populations on canine skin. *Vet Dermatol* 2015b, 26:278-e61.
- Nègre A, Bensignor E, Guillot G. Evidence-based veterinary dermatology: a systematic review of interventions for *Malassezia* dermatitis in dogs. *Vet Dermatol* 2008, 20:1-12.

Fungal rhinosinusitis: emerging agents of aspergillosis in cats

Professor Vanessa R. Barrs, Faculty of Veterinary Science, School of Life and Environmental Sciences, The University of Sydney NSW 2006 Australia

Mycoses are increasingly recognised in companion animals. Most, including aspergillosis, occur in apparently immunocompetent hosts. Almost half of all reported cases of feline *Aspergillus* rhinosinusitis occurred in Australia. Disease has also been reported in the United States, Japan, United Kingdom and mainland Europe. Fungal rhinosinusitis occurs in two distinct forms; sino-nasal aspergillosis (SNA), which is typically non-invasive and sino-orbital aspergillosis (SOA), which is focally invasive. The majority of Australian cases were SOA caused by a novel species, identified first in cats and named *Aspergillus felis*. Like *Aspergillus udagawae*, itself an emerging agent of aspergillosis in humans, *A. felis* belongs to the *Aspergillus viridinutans* complex in section *Fumigati*. These medically significant fungi are characterised by high innate levels of antifungal resistance and close morphological resemblance to *A. fumigatus*. *A. udagawae* is the second most common cause of SOA in cats and *A. wyomingensis*, another member of the *Aspergillus viridinutans* complex has been isolated from a cat with SOA. Other cryptic species within section *Fumigati* have been identified in cats with SNA and SOA. The most common species isolated from cases of feline SNA are *A. fumigatus* sensu stricto and *A. niger* complex.

Advances have been made in the diagnosis of feline fungal rhinosinusitis. Serum galactomannan detection is not useful as a screening diagnostic test due to low sensitivity and only moderate specificity, but may be useful to monitor fungal load in individual cats that test positive. Detection of *Aspergillus*-specific antibodies by agar gel double immunodiffusion also has low sensitivity. However, IgG ELISA has excellent sensitivity and specificity for diagnosis, and is well suited as a non-invasive diagnostic test. Computed tomographic findings have also been characterised. *Aspergillus* species can be readily cultured from tissue biopsies or nasal fungal plaques. Cryptic species can be distinguished from *A. fumigatus* sensu stricto by failure to grow at 50 °C. However, definitive identification requires comparative sequence analysis. The universal DNA barcode nuclear ribosomal internal transcribed spacer region is

unreliable for definitive species identification and should be combined with calmodulin as a secondary identification marker.

The prognosis for feline SNA is good with treatments involving topical debridement of fungal plaques and topical and/or systemic azole therapy. The prognosis for SOA is poor. Some cats have been cured using combination therapy with amphotericin B, posaconazole and terbinafine. Caspofungin has also been used in individual cases, and the pharmacokinetics of this drug in cats has recently been established.

Cryptococcosis in companion animals and wildlife

¹**Richard Malik DVSc MVetClinStud Stud PhD FACVS FASM**

²Mark Krockenberger BVSc PhD FACVS MASM, ²Laura Schmertmann BSc (vet)
BVSc

¹Centre for Veterinary Education and ²Faculty of Veterinary Science, The University of Sydney. Richard Malik is an Adjunct Professor at Charles Sturt University

Cryptococcosis is one of the best characterized fungal infections of mammals. Indeed, it is perhaps the most cosmopolitan fungal pathogen, being capable of producing disease in mammals, birds, reptiles, zebra fish, moth larvae, nematodes and amoeba. The environmental niche of the organism resides in nature, with circumstantial evidence suggesting that this may be within tree hollows in close association with organic matter including bark, leaves and soil enriched by avian or mammalian guano. The pathogenic species within this genus typically consist of the *Cryptococcus neoformans/gattii* species complex (which might eventually be divided taxonomically into eight separate species, the nosology of which is currently controversial), and less virulent species like *Cryptococcus laurentii* that are not as thermotolerant. In host tissues, the organism grows as a yeast, which multiplies by narrow-necked budding, whereas in nature likely it undergoes a variety of mating strategies (budding, and also both conventional and same-sex mating (haploid fruiting), depending on specific circumstances) that involve filamentation, cross clamp formation and the production of basidiospores. These spores are the likely infectious propagules that penetrate the respiratory tract to establish colonization and subsequently infection of mammalian hosts. The key virulence factors of *Cryptococcus* have been well characterized, and involve (i) ability to grow at mammalian and even avian body temperature, (ii) melanin production, (iii) elaboration of a complex polysaccharide capsule and (iv) key enzymes including laccase, urease and phospholipase, (v) plus the ability to develop special cellular adaptations which favour survival in mammalian tissues, such as 'titan cell' formation and tubular mitochondria. Many of these adaptations have arisen because of the need to survive and

multiply in hostile environmental niches, where solar irradiation, high temperature, competing microorganisms (including *Acanthamoeba* and nematodes) all form part of the natural milieu. The history of *Cryptococcus* and cryptococcosis is rich and has been extensively reviewed in the landmark monograph by Casadevall & Perfect, and more recently by Heitman and colleagues' text. Of course there have been cogent observations from the diagnosis and treatment of human patients and detailed investigations at the laboratory bench. It would be fair to say, however, that insights from analysis of naturally-occurring and experimentally-induced disease in animals have made a critical contribution to our understanding of cryptococcal pathogenesis and epidemiology. This emphasizes the value of the 'one medicine/one health' approach embraced by ISCHAM in relation to fungal disease investigations. In particular, there are striking insights into the 'host:pathogen:environment interaction' from a veterinary perspective, including early infection, the role of asymptomatic colonization and spontaneous cure in some infected individuals with limited disease, which has been inferred but not observed for human patients. This presentation will focus on the impact of veterinary science to our understanding of cryptococcosis. We will use the conceptual framework of the outstanding review by Robin May, Kirsten Nielsen and colleagues **Cryptococcus: From environmental saprophyte to global pathogen in *Nature Reviews Microbiology* Feb 2016 14: 106-117** – and concentrate on how veterinary mycologists have provided some of the most striking insights into this global fungal pathogen, drawing especially on our experiences in Australia in relation to cryptococcosis in companion animals (cats, dogs, ferrets, horses, parrots) and wildlife, especially the most iconic of all Australian mammals, the koala.

***Microspphaeropsis arundinis* - an emerging infectious disease of humans and animals in Australia**

¹Richard Malik DVSc MVetClinStud Stud PhD FACVS FASM

²Mark Krockenberger BVSc PhD FACVS MASM, ³Catriona Halliday BSc PhD MASM

¹Centre for Veterinary Education and ²Faculty of Veterinary Science, ³Centre for Infectious Diseases and Microbiology Laboratory Services, Westmead Hospital, Westmead, New South Wales, Australia, The University of Sydney. Richard Malik is an Adjunct Professor at Charles Sturt University

Microspphaeropsis arundinis is an anamorphic dematiaceous fungus ubiquitous in soil and fresh water. It typically inhabits terrestrial plant hosts and has a well-known association with *Arundo donax*, a garden escape weed commonly known as ‘elephant grass’. *M. arundinis* (fungi imperfecti) is a coelomycete, which encompasses an emerging group of pathogens capable of causing soft tissue infections, mostly in immunocompromised human patients. Such disease typically arises secondary to traumatic inoculation of fungal elements. The infection may then spread to contiguous subcutaneous tissues or via the lymphatics in a sporotrichoid manner. The first reports of this organism causing disease occurred 12 years ago. Since then an increasing number of cases have been encountered. In cats, lesions are most consistently encountered on their distal extremities, on or near the toes, although scratch injuries can cause cutaneous infections on the cat’s face. In 2004, Kluger *et al.* reported the first *M. arundinis* infection in a 7-year-old cat living in suburban Sydney. It had a granulomatous lesion within the deep tissues of the distal forelimb. The cat had a concurrent *Fusarium chlamydosporum* infection affecting another limb. A few months later, Pendle *et al.* from Royal North Shore Hospital reported the same organism as a cause of disease in two immunocompromised human patients, with archival information on a third case, a patient with acute myeloid leukaemia seen 23 years earlier. Since the first report by Pendle and colleagues there have been at least 7 additional *M. arundinis* infections reported in human patients, individual cases being seen at St George Hospital,

Wollongong Hospital, Concord Hospital, Westmead Hospital, St Vincent's Hospital and Prince of Wales Hospital, and a further case from Florida (in the USA). Five Australian cases were recently been collated and published by Chen and colleagues. In the veterinary arena, we continue to see *M. arundinis* infections in cats along the East coast of Australia. It is currently the most common cause of feline subcutaneous phaeohyphomycosis, with 5 cases between 2009 and 2012. There appears to be neither an age predisposition in cats nor any gender preponderance. Geographically, two cats were from Sydney, two were from the Central Coast, one each from Newcastle and Wollongong, while the last case was from Brisbane. All cats lived in coastal environments, which are becoming hotter and more humid due to global warming. Lesions are generally present on distal extremities of either the forelimbs or hind limbs. Finally, we recently encountered our first canine case last November. In veterinary practice, repeat samples for culture and antifungal susceptibility testing are often difficult to obtain because serial specimen collection requires sedation or anaesthesia with additional costs and morbidity. To overcome this limitation, we have found that there is sufficient fungal nucleic acid preserved in methanol-fixed, DiffQuik®-stained smears to permit successful DNA purification, panfungal PCR and sequence analysis using material scraped from cytological specimens. These infections have a favourable prognosis in both human and feline patients, using monotherapy using drugs such as itraconazole and posaconazole, although feline patients appear to often benefit from cytorreduction of infected tissues. Human patients suffering from these infections often have a known cause of immunodeficiency, such as drugs like tacrolimus, cyclosporine or prednisolone used in renal transplant recipients.

Sporotrichosis: an “old” disease but an ongoing threat for animal and human health

Guillot Jacques^{1,2}, Chermette René^{1,2}

1. Research group Dynamyc, UPEC, EnvA, Medicine Faculty, Créteil, France

2. Parasitology-Myology-Dermatology Unit, DSBP, Ecole nationale vétérinaire d'Alfort, Maisons-Alfort, France

Sporotrichosis is due to telluric dimorphic fungi, which belong to the genus *Sporothrix*. The disease was first described in humans by Schenk in 1899 in the United States and was further reported in a wide variety of domestic and wild animals including cattle, goat, dromedary, donkey, horse, mule, cat, dog, poultry as well as various species of wild carnivores, rodents, suids, armadillos, non-human primates, marine mammals and birds. Multilocus sequencing combined with morphological and physiological data support the separation of at least four distinct *Sporothrix* species (*S. schenckii*, *S. lurai*, *S. globosa* and *S. brasiliensis*).

Sporotrichosis has a worldwide distribution and is enzootic on all continents although cases from Western Europe have been reported less frequently. Prevalence is higher in tropical and subtropical areas. *Sporothrix* organisms are usually inoculated through the skin from soil or vegetation that has been contaminated with infective spores. Wounds, various traumas with small pieces of wood, grass awns or spines are predisposing factors for infection (sporotrichosis is sometimes called “gardener’s disease” in humans). Amongst domestic animals, sporotrichosis is of particular clinical importance in horses and carnivores but cats are most susceptible with a high rate of multiplication of the fungus. Contrary to other hosts, yeasts are abundant in sporotrichosis lesions of cats, which are sources of direct contamination of humans through bites, scratches and even

after contact with intact skin. Sporotrichosis is considered to be a contagious disease with a potential zoonotic hazard, especially from cats.

In 2015, Zhang *et al.* demonstrated that the pathogenic clade of four *Sporothrix* species comprises nine subclusters, which often have limited geographic distribution and are separate from each other. In contrast, *S. globosa* exhibits consistent global distribution of identical AFLP types, suggesting another type of dispersal. *Sporothrix brasiliensis* is known to be involved in an expanding zoonosis (especially in Brazil) and is transmitted by cats, whereas *S. globosa* infections originate from putrid plant material, causing a sapronosis. *Sporothrix schenckii* the most variable species within the clade, also had a plant origin, with ecological similarities to that of *S. globosa*.

References

- Zhang Y, *et al.* Phylogeography and evolutionary patterns in *Sporothrix* spanning more than 14 000 human and animal case reports. *Persoonia* 2015, 35:1-20.
- Rangel-Gamboa L, *et al.* Update of phylogenetic and genetic diversity of *Sporothrix schenckii* sensu lato. *Med Mycol* 2016 54:248-55.
- Rodrigues AM, *et al.* Phylogenetic analysis reveals a high prevalence of *Sporothrix brasiliensis* in feline sporotrichosis outbreaks. *PLoS Negl Trop Dis* 2013 20:e2281.

Protothecosis in animals in Australia

¹Richard Malik DVSc MVetClinStud Stud PhD FACVS FASM

²Mark Krockenberger BVSc PhD FACVS MASM, ³Patrizia Danesi,

¹Centre for Veterinary Education and ²Faculty of Veterinary Science, The University of Sydney, ³Istituto Zooprofilattico Sperimentale delle Venezie, Legnaro, Italy

Richard Malik is an Adjunct Professor at Charles Sturt University

The genus *Prototheca* includes algal organisms which under certain circumstances can become pathogens of mammalian hosts. The disease entities caused by *Prototheca* in Australia are quite syndromic, comprising (i) granulomatous mastitis in dairy cattle (ii) localised skin disease in cats, typically involving the distal limbs (ii) severe colitis in dogs, especially Boxer dogs, their crosses and French bulldogs, with the propensity to disseminate haematogenously to disparate sites including heart, bone, eye and brain. Bovine protothecal mastitis is beyond my experience, as I am a small animal clinician. It results from an ascending infection of the teat canal from an unhygienic environment. As a result, it is seen almost invariably as a problem affecting dairy cattle, because of the pendulous nature of their udders and trauma to the teat canal from milking machines which favour establishment of infections. Treating an individual affected cow is usually not rewarding and the emphasis is therefore on improving hygiene measures in the dairy and possibly the use of biocides to decrease the number of infectious propagules in the environment. Feline protothecosis is an unusual disease of cats, usually consisting of solitary or multifocal lesions affecting the distal extremities, often occurring in immunocompromised patients, following penetrating injury in which there is heavy environmental presence of *Prototheca* forms. Treatment involves use of antifungals such as itraconazole and posaconazole, combined with surgical excision of heavily infected tissues using *en bloc* resection, where possible. The tendency for lesions to be located on or near the digital or stopper pads can make surgical intervention challenging, and recurrence and the requirement for a second surgery is not unusual. The most fascinating and the most devastating manifestation of protothecosis in domestic animals concerns the disease in dogs. A variety of breeds have been afflicted according to the

limited literature concerning this orphan disease, however increasingly the preponderance of Boxers and Boxer hybrids has become obvious. The initial signs of canine protothecosis are those of colitis – fresh blood in the stool, excessive mucus, frequent defecation and straining. Typically there is minimal to no response to standard treatment regimens for colitis including changes in the diet, metronidazole or sulphasalazine. A high index of suspicion for protothecal colitis at this stage, with procurement of rectal scrapes or endoscopic colonic biopsies, will result in a timely diagnosis. However, if empiric treatments are trialed over a protracted period, the disease process spreads via penetration of the thin walled colonic veins, resulting in widespread haematogenous dissemination to almost any tissue, but with a tropism for the brain, heart, eye and bone. By the time widespread dissemination has occurred, treatment is virtually futile, whereas if infection is caught early, combination therapy using various amphotericin B formulations combined with modern azoles can produce a robust clinical emission, and occasional cases can be cured with long-term or life-long therapy. The most striking recent insight into this disease has come from Kenny Simpson's Cornell group who have observed that Boxer dogs affected with systemic protothecosis do so as a result of underlying granulomatous colitis, which in turn is the result of a genetically-programmed immune defect most likely affecting innate immunity. This would suggest that targeted therapy for invasive/adherent *Escherichia coli* using drugs like enrofloxacin should be considered as part of the therapeutic regimen in dogs with protothecosis, especially when disease is limited to the colon.

Scedosporiosis in companion animals: another emerging mycosis?

Vanessa R. Barrs¹, J. Talbot¹, P. Martin¹, S. Kidd².

¹Faculty of Veterinary Science, School of Life and Environmental Sciences, The University of Sydney NSW 2006 Australia; ² National Mycology Reference Centre, Microbiology and Infectious Diseases, SA Pathology SA 5000

Scedosporiosis is a rarely reported mycosis of dogs and cats. Pathogenic agents include *Lomentospora prolificans* (previously *Scedosporium prolificans*) and species of the *S. apiospermum* complex, most notably *S. apiospermum* and *S. aurantiacum*. Only four cases of fungal rhinosinusitis due to *Lomentospora/Scedosporium* species have been reported in dogs (n=3) and cats (n=1) previously. Other reported infections in dogs include disseminated scedosporiosis, mycetomas and keratomycosis.

Records of the Veterinary Pathology Diagnostic Services database at the University of Sydney, and of the National Mycology Reference Centre in Adelaide, South Australia were searched from 2000-2015 for isolates of *Lomentospora/Scedosporium* from clinical submissions from dogs and cats. There were 14 isolates from 10 dogs and 4 cats for which infection site was recorded, including 4 isolates from 2000-2004, 3 from 2005-2009 and 7 from 2010-2015.

Infections included fungal rhinosinusitis in 6 cases (3 dogs, 3 cats) due to *S. apiospermum* complex (n=5) or *L. prolificans* (n=1); chronic otitis externa in 4 cases (3 dogs, 1 cat) of which 2 had concurrent otitis media, due to *S. apiospermum* complex (n=2) or *L. prolificans* (n=2); disseminated disease in 3 dogs due to *S. apiospermum* complex (n=1) or *L. prolificans* (n=2), and one case of keratomycosis in a dog due to *L. prolificans*. Of the fungal rhinosinusitis cases, two infection in cats occurred as co-infections with *Aspergillus fumigatus* sensu stricto. One of the cases of disseminated disease in dogs due to *L. prolificans* occurred subsequent to chronic administration of prednisolone and cyclosporine.

Scedosporiosis is an emerging mycosis of humans. *S. apiospermum* is commonly isolated from soil, sewage and polluted waterways, while *L. prolificans*, isolated from soil and potted plants, has a more restricted geographical distribution. Human infections of *L. prolificans* are predominantly from Australia and Spain. Interestingly, 6 of the 14

isolates of *Lomentospora/Scedosporium* from cats and dogs in this series were *L. prolificans*.

These data indicate that *Lomentospora/Scedosporium* spp. may be a more common cause of fungal rhinosinusitis in cats and dogs than previously thought, and that the number of isolates in the last five years was almost double that of the previous two consecutive five-year periods.

Aspergillosis: a real threat for poultry industry?

Guillot Jacques^{1,2}, Risco Veronica^{1,2}, Chermette René^{1,2}, Arné Pascal^{1,3}

1. Research group Dynamyc, UPEC, EnvA, Medicine Faculty, Créteil, France

2. Parasitology-Myiology-Dermatology Unit, DSBP, Ecole nationale vétérinaire d'Alfort, Maisons-Alfort, France

3. Animal Production dept, DPASP, Ecole nationale vétérinaire d'Alfort, Maisons-Alfort, France

Aspergillus species are found worldwide in humans and in almost all domestic animals as well as in many wild species, causing a wide range of diseases from localized conditions to fatal disseminated infections or even from an allergic reaction to inhaled spores. Both host and fungus characteristics explain the particular susceptibility of birds to *Aspergillus* infection. In poultry farms, many environmental stressors are potentially present, where excessive ammonia and moisture, inappropriate temperature, degraded litter, feed contamination with mycotoxins and competing pathogens may affect birds' immunocompetence. Aspergillosis has been reported in almost all domesticated avian species and production types. Clinical manifestations of aspergillosis in poultry depend on the infective dose, the spore distribution, pre-existing diseases, and the immune response of the host. Active fungal proliferation and sporulation of *A. fumigatus* on organic material produces large amounts of airborne small-sized spores that are easily dispersed in air, then potentially inhaled and deposited deep in the respiratory tract. Discriminatory molecular genotyping based on multilocus microsatellite panels demonstrated that the environment of diseased animals may be a source for *A. fumigatus* infection and that either multiple or single genotypes linked infections could

occur in confirmed cases. Susceptible hosts will develop polymorphic clinical forms in relation to either localized or disseminated lesions.

Economic significance of aspergillosis is most readily apparent in turkey production where disease occurs late in the growing cycle or primarily affects costly breeder toms. In spontaneous outbreaks, the mortality ranged between 4.5% and 90%, whereas the age of diseased birds varied from 3 days to 20 weeks. In poultry farms, with acute aspergillosis the mortality rate may rise slightly or increase suddenly, then peaks over a few days, and then returns to the initial state. In addition to direct losses related to mortality, feed conversion and growth rate associated with reduced welfare in recovering birds remain poor. Airsacculitis remains a major reason for carcass condemnation at slaughter inspection.

References

- Arné P, *et al.* *Aspergillus fumigatus* in Poultry. *Int J Microbiol* 2011:746356.
- Beernaert LA, *et al.* *Aspergillus* infections in birds: a review. *Avian Pathol* 2010, 39:325-31.
- Seyedmousavi S, Guillot J, Arné P, *et al.* *Aspergillus* and aspergilloses in wild and domestic animals: a global health concern with parallels to human disease. *Med Mycol* 2015 53(8):765-97.
- Thierry S, *et al.* Multiple-locus variable-number tandem repeat analysis for molecular typing of *Aspergillus fumigatus*. *BMC Microbiol* 2010, 10:315.

Azole resistance in *Aspergillus fumigatus* in EU: why it is increasing in the world?

Dr. Seyedmojtaba (Amir) Seyedmousavi

Laboratory of Clinical Infectious Diseases (LCID), National Institute of Allergy and Infectious Diseases (NIAID), National Institutes of Health (NIH), Bethesda, MD 20892

United States of America

Tel: [\(301\) 402-5139](tel:3014025139), Email: Seyedmousavi@nih.gov

The importance of aspergillosis in humans and various animal species has increased over the last decades.

In humans, *Aspergillus fumigatus* is the most common and life-threatening airborne opportunistic fungal pathogen, especially significant among immunocompromised hosts, causing a wide range of diseases from localized infections to fatal disseminated diseases, as well as allergic responses to inhaled conidia.

Aspergilloses in animals are caused by *A. fumigatus* and a few other *Aspergillus* species, primarily as a respiratory infection that may become generalized; however, tissue predilection is highly variable among species.

The medical triazoles, itraconazole, voriconazole, and posaconazole, are the most widely used drugs for the management of infections caused by the saprophytic mold *A. fumigatus*. However, acquired azole resistance in *A. fumigatus* is an emerging problem that compromises the clinical efficacy of azole antifungals.

Several mutations in the Cyp51A gene of *A. fumigatus* affect the activity of all mold-active antifungal azoles. These mutations result in the complete loss of activity of a specific azole and are commonly associated with cross-resistance to other azoles.

While azole resistance may emerge during antifungal therapy of individual azole-treated hosts, selection of resistance can also occur in the environment.

Importantly, the selection for azole resistance within the environment poses an emerging global threat for human and animals as mutations associated with

environmental resistance have now been detected with increasing frequency in multiple European countries, Asia, the Middle East and Africa.

References:

1. Seyedmousavi S. et al. 2015. Azole Resistance in *Aspergillus fumigatus*: Mechanisms, Route of Resistance Selection, and Clinical Implications, p 1-17. In Gotte M, Berghuis A, Matlashewski G, Wainberg M, Sheppard D (ed), Handbook of Antimicrobial Resistance doi:10.1007/978-1-4939-0667-3_22-1. Springer New York.

2. Seyedmousavi S. et al. 2015. *Aspergillus* and aspergilloses in wild and domestic animals: a global health concern with parallels to human disease. *Med Mycol* 53:765-797.

Azole farm fungicide and azole resistance in *Aspergillus fumigatus*: is it increasing in Japan ?

Rui Kano

Veterinary Pathobiology, College of Bioresource Sciences, Nihon University, 1866 Kameino, Fuzisawa, Kanagawa 252-0880, Japan

Azole resistance in *Aspergillus fumigatus* has been reported worldwide. This resistance is mainly due to a point mutation in the 14 α -sterol demethylase (*CYP51A*) gene, which is the target of azoles. The mutation induces resistance to several azoles in *A. fumigatus*, including itraconazole (ITZ), which is used commonly to treat human aspergillosis. Isolates of *A. fumigatus* from farms were first reported to be resistant in the Netherlands, and resistances have been reported worldwide.

In these studies, however, the relationship between farm environments and azole resistance in *A. fumigatus* was not studied in Japan. Therefore, isolates of *A. fumigatus* from the farm at Nihon University were examined with regard to azole resistance.

In our study, 50 isolates of *A. fumigatus* were obtained from a farm where tetraconazole has been sprayed twice a year for more than 15 years. Tetraconazole, one of common fungicide in Japan and was selected in this study to evaluate the farm environment and to confirm the incidence of azole resistance in *A. fumigatus*. The mean minimal inhibitory concentration (MIC) of 50 isolates was 0.74 (0.19-1.5) mg/L against ITZ. This MIC value was below the medical resistance level of ITZ. The sequence of *CYP51A* from isolates indicated no gene mutations in isolates from the farm.

Next, we tried to induce resistance to tetraconazole *in vitro*, in strains of *A. fumigatus* from a farm and then investigated mutation and expression of their *CYP51A*, *CYP51B*, and multidrug resistance (MDR) genes. No gene mutations were detected in the *CYP 51A* sequence amplified in these strains. RT-PCR of *cyp51A* and *cyp51B* indicated that the tetraconazole resistant strains more highly expressed these genes than the susceptible strain in tetraconazole containing medium.

Therefore, spraying of tetraconazole at standard dosages does not induce azole resistance in *A. fumigatus*.

ACKNOWLEDGEMENTS TO SPONSORS

zoetis[®]

K 共立製薬

Cica Kanto Chemical Co., Inc.

KIRIKAN LTD.[®]

株式会社ファームプレス

